










































# Appendix

## Apparatus

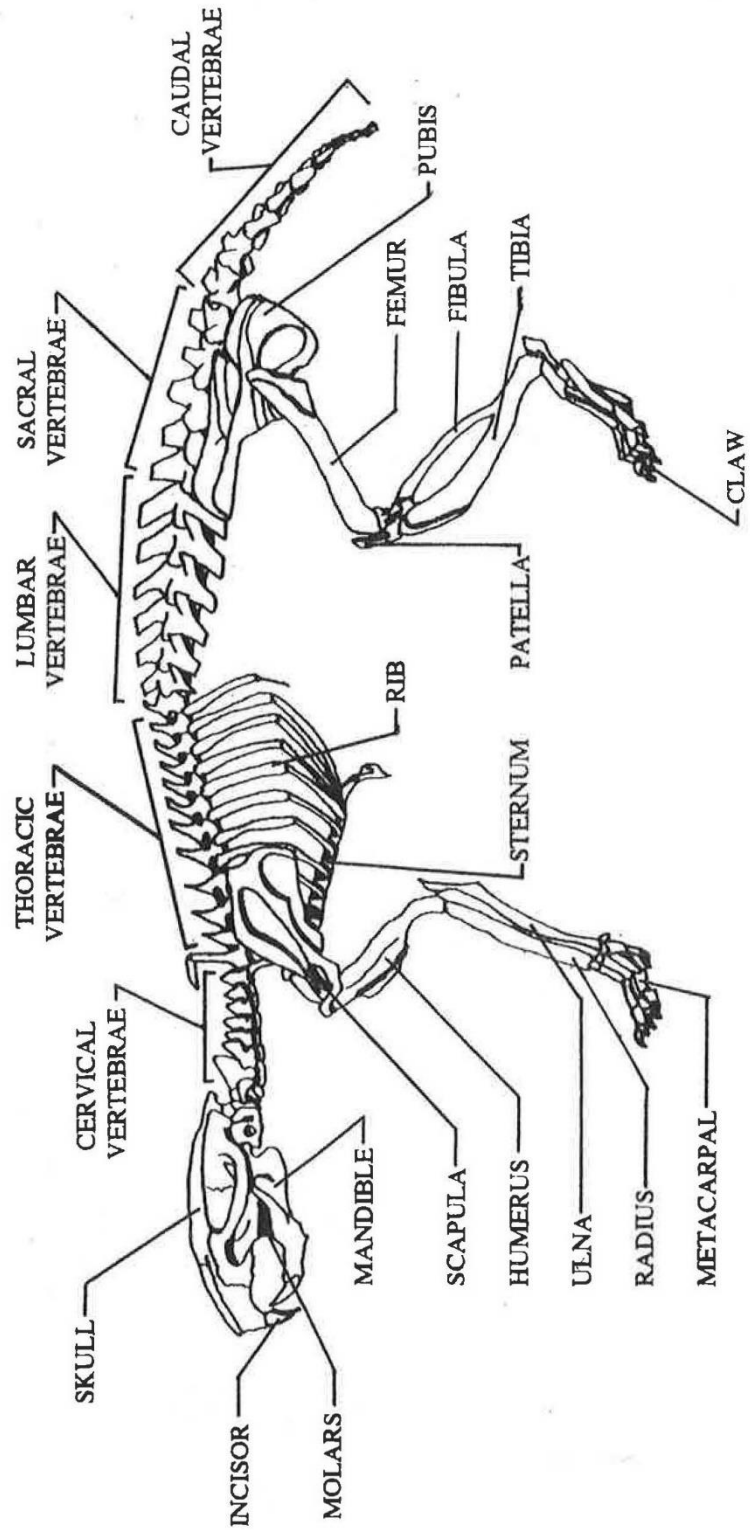


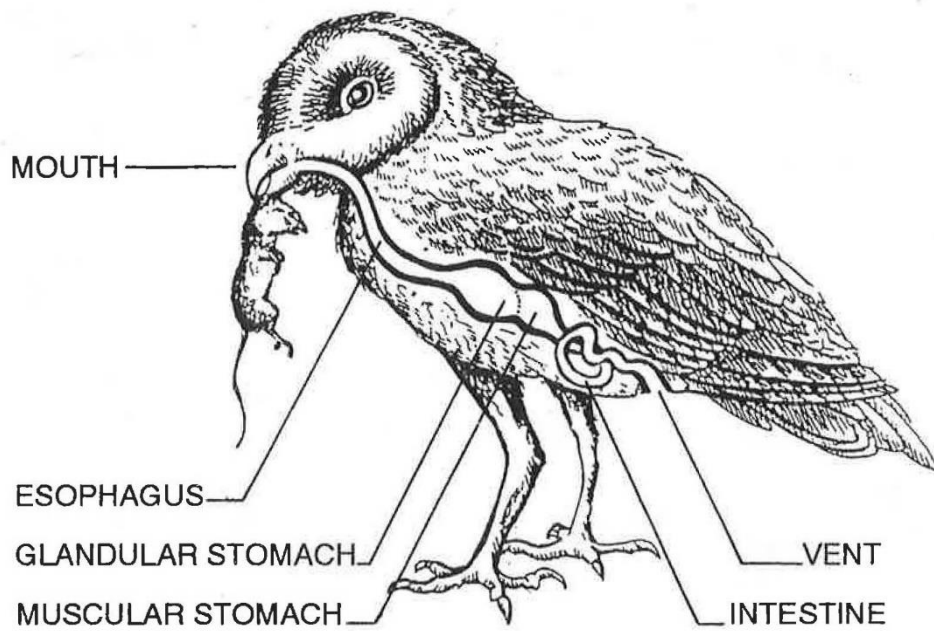
# IDENTIFYING OWL PELLET CONTENTS

	RAT	VOLE	MOUSE	SHREW	BIRD
SKULL AND JAW					
JAW LENGTH MILLIMETERS	17-30	15-20	10-15	7-14	15-40
TOOTH TYPE	LOBED	ANGLED	LOBED	POINTED	NONE
SHOULDER BLADE					
HIP					
UPPER LEG					
LOWER LEG					
RIB					
BACK BONES					
FOOT					

# VOLE

## SKELETAL ANATOMY





The digestive tract of a Barn Owl